


Real World Results of a Dynamic Scoring Device in Calcified Femoropopliteal Vessels.

John Pigott, MD, Director Endovascular Surgery, Jobst Vascular Institute, Promedica Healthcare Systems, Toledo, OH

Aims: Calcified vessels are a current challenge in peripheral artery disease. Calcified vessels are resistant to dilatation and exhibit higher rates of plaque dissection and lesser degrees of luminal gain. Advanced techniques to prepare the vessel are currently warranted to improve treatment outcomes. Results of a dynamic scoring device in calcified femoropopliteal vessels were evaluated.

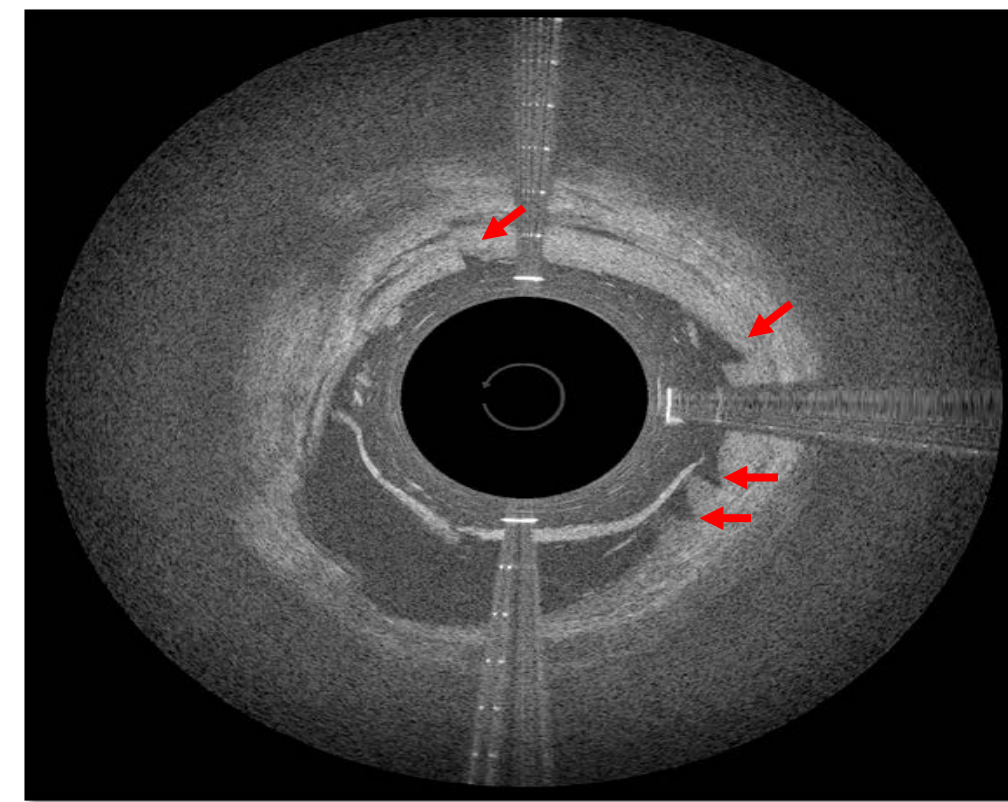
Technology Overview: The dynamic scoring device evaluated is a 6 French, 0.18 guidewire compatible device, purposely engineered with 3 atherotomes to modify plaque during pull back. It can be rotationally controlled to provide multiple linear scores, facilitating in the preparation of the vessel for angioplasty.



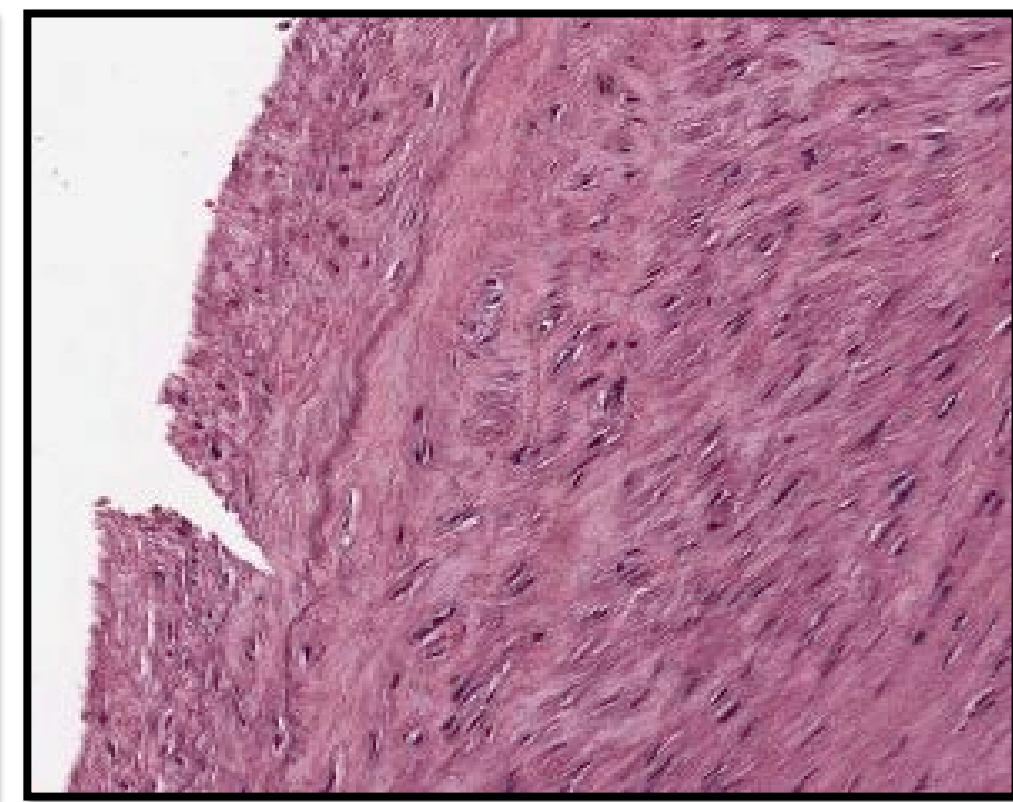
Sheath Size	6 French
Wire Compatibility	.014 and .018
Catheter Length	40cm and 120cm
3 Atherotomes (Proximal)	0.01" in Height
FDA / CE Mark Indication	Facilitate Dilatation of Stenoses of Femoropopliteal and AVF/AVG

Dynamic Scoring® Technology

- Creates Precise Longitudinal Micro-Incisions
- Atherotomes (proximal) Interact with the Vessel Surface at 1 atm.
- Facilitates an improvement in Vessel Compliance
- Creates an Environment for Optimal Angioplasty Results.



OCT Image of Micro-Incision

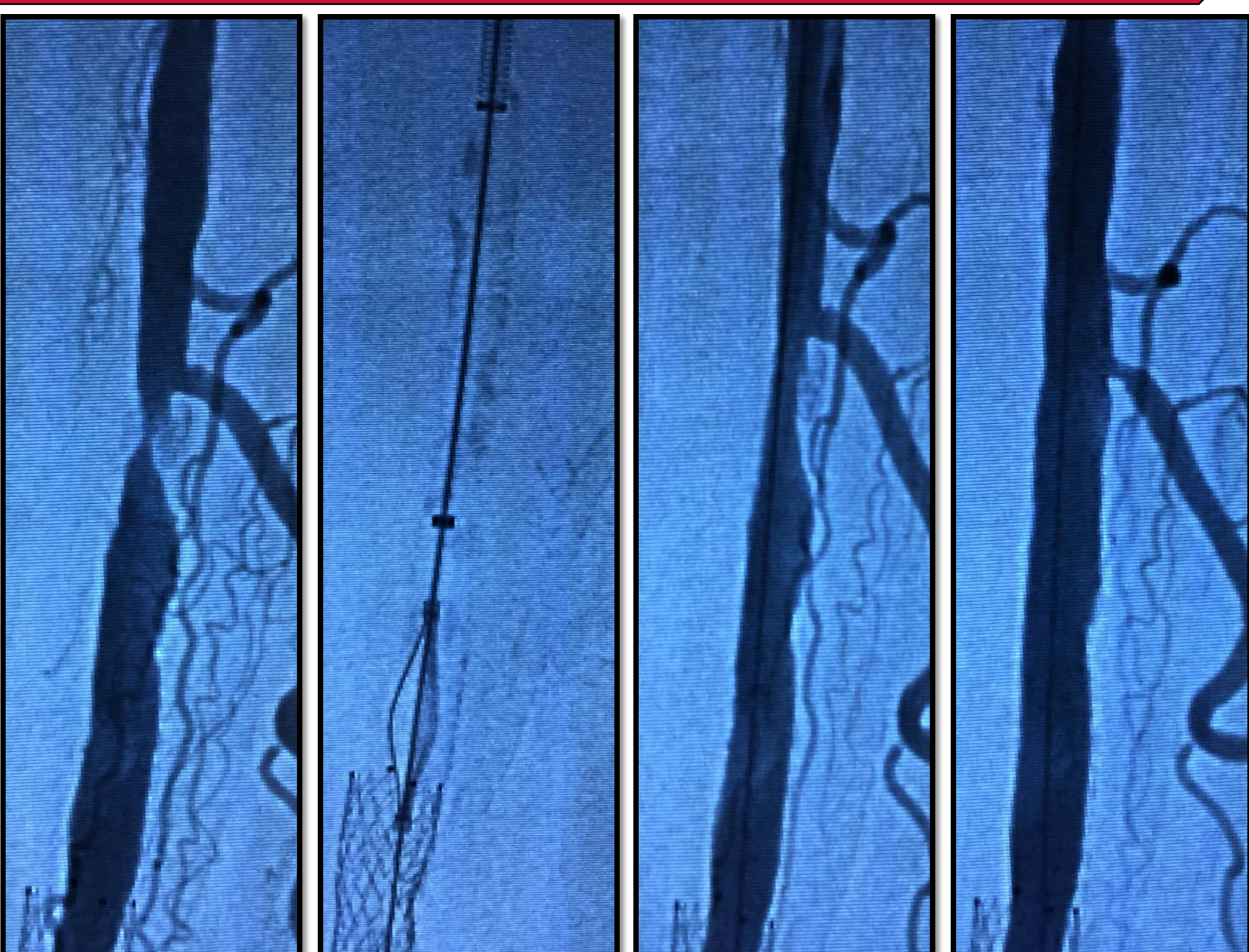


Cadaveric Human SFA

Methods:

The present study examined 237 voluntarily provided case reports (51 operators in 32 hospital systems) with femoropopliteal lesions. Initially, the vessel was treated with the dynamic scoring device followed by a drug coated balloon (DCB) or plain old balloon angioplasty (POBA). Study case report forms were classified by calcification severity: none to mild and moderate to severe, as per operator visual estimation and assessment.

Case Study



Diagnostic

FLEX Deployed

Post FLEX

Post FLEX+DCB

Results	None – Mild	Moderate - Severe
Number of Cases	115	122
Lesion Length (mm)	130	142
Pre-Stenosis (%)	90 (60 – 100)	93 (60 – 100)
Luminal Gain Post FLEX (%)	23 (0 – 80)	26 (0 – 89)
Residual Stenosis (%)	8 (0 – 30)	10 (0 – 50)
DCB Use (%)	75	72
Opening Pressure (atm)	4 (2 – 12)	4 (2 – 8)
Maximal Pressure (atm)	10 (4 – 16)	9 (4 – 18)
No Dissections (%)	96	92
Flow Limiting Dissection (%)	0	0
Provisional Stenting (%)	19	19
Technical Success (%)	98.7	

Rutherford Class 3	Opening Pressure: 4 atm
Lesion Length: 20 mm	Maximal Pressure: 9 atm
Calcification: Severe	Atherectomy: None
Pre-Stenosis: 95%	Dissection: None
Number of FLEX Passes: 3	Emboli: None
Post FLEX Stenosis: 60%	Residual Stenosis: 0%
Luminal Gain Post FLEX: 35%	

Conclusions: A high degree of technical success was achieved with the evaluated dynamic scoring device. Acute results revealed significant luminal gain with the device. The provisional stent use and dissection rates were low. Significant change in vessel wall compliance is suggested by the low balloon opening pressures observed. The device achieved acceptable results in vessels with none to mild calcification, as well as moderate to severe. Further studies are warranted.